

COMPARISON OF HUMERAL INTERLOCKING NAIL AND COMPRESSION PLATING IN MANAGEMENT OF HUMERUS SHAFT FRACTURE

Mohd Faheem Ansari¹, Saurabh Saxena¹, Chetan Singh¹

¹Assistant Professor, Department of Orthopaedics, GSVM, Kanpur, Uttar Pradesh, India

Received : 30/11/2022
Received in revised form : 02/01/2023
Accepted : 15/01/2023

Keywords:

Dynamic compression plating,
Interlocking nail, shaft.

Corresponding Author:

Dr. Chetan Singh,
Email: dr.chetansingh823@gmail.com

DOI: 10.47009/jamp.2023.5.1.197

Source of Support: Nil,
Conflict of Interest: None declared

Int J Acad Med Pharm
2023; 5 (1); 955-959



Abstract

Background: To compare humeral interlocking nail and compression plating in fracture of shaft of humerus cases. **Materials and Methods:** One hundred twenty cases of fracture of shaft of humerus involving either gender in age range 18- 60 years were divided into 2 groups of 60 each. Internal fixation by humeral interlocking nails was performed on Group I, and internal fixation by dynamic compression plating, with or without bone grafting, was performed on Group II. AO classification, mode of injury, level of injury, side, range of elbow joint movements, DASH score and complications in both groups were recorded. **Result:** Age group 18-28 years had 14 patients in group I and 7 in group II, 28-38 years had 18 in group I and 22 in group II, 38-48 years had 15 in group I and 20 in group II and 48-60 years had 13 in group I and 11 in group II. Mode of injury was RTA in 46 in group I and 41 in group II, fall in 10 in group I and 12 in group II and violence in 4 in group I and 7 in group II. In 22 cases in group I and 23 in group II had A3 type of fracture and B2 was seen in 21 and 18 patients respectively. Level of injury was upper 1/3rd seen in 14 and 19, middle 1/3rd in 37 and 31 and lower 1/3rd in 13 and 20 patients in group I and II respectively. Left side was involved in 32 cases in group I and 26 in group II and right side in 28 and 34 in group I and II respectively. Range of movement pre- operatively in group I was 8-128 degrees and in group II was 4-130 degrees and post- operatively in group I was 4-134 degrees and in group II was 5-130 degrees. In 22 cases in group I and 32 in group II DASH score was excellent, 13 cases in group I and 10 in group II had good, 20 in group I and 16 in group II had fair and 5 in group I and 2 in group II had poor DASH score. Complications seen were implant failure 1 in group I and 2 in group II, non- union 2 in group I and 3 in group II, shortening seen in 1 in group I and 2 in group II, superficial infection 1 in group I and 2 in group II, and deep infection 1 in group I and 2 in group II. The difference was non-significant ($P > 0.05$). **Conclusion:** Both humeral interlocking nail and dynamic compression plating can be considered in the management of humeral shaft fractures.

INTRODUCTION

The humerus bone is the long bone located in the upper arm. It extends from the shoulder joint to the elbow joint and is one of the major bones in the human skeleton. The humerus bone is responsible for providing structural support to the upper arm and facilitating movement of the arm.^[1]

Fractures of the humerus bone can occur due to trauma, falls, or repetitive stress. Fractures may involve the proximal end, shaft, or distal end of the bone.^[2] Orthopaedic surgeons frequently see humeral shaft fractures, which make up around 3% of all fractures. Intense pain, bruising, swelling,

restricted arm movement, deformity, or a popping or cracking sound at the time of injury are all signs of humerus bone fractures.^[3] You must consult a doctor right away if you think you may have a humerus fracture. As improvements are achieved in both surgical and non-surgical therapy, the way these injuries are treated is always changing. The majority of humeral shaft fractures can be treated non-operatively with expected excellent to good results. Muscles cover the entire humeral shaft, and the fracture pieces have good blood supply. Direct and indirect trauma can result in humeral shaft fractures. Like any other wound, the healing of the fracture is dependent on the flow of blood.^[4]

Although there are indications for primary or secondary operational treatment in specific circumstances, the majority of humeral shaft fractures are treated non-operatively. As a result of its lower complication rate and quicker time to union than intramedullary nailing, open reduction and internal fixation (ORIF) using plates and screws is still regarded as the gold standard for surgical therapy.^[5] Considering this, we performed present study to compare humeral interlocking nail and compression plating in fracture of shaft of humerus cases.

MATERIALS AND METHODS

A sum total of one hundred twenty cases of fracture of shaft of humerus involving either gender in age range 18- 60 years were recruited for the prospective, observational study. Ethical review board of the institute approved the study. All enrolled patients agreed to actively participate in the study.

Data such as name, age, gender etc. was recorded. There were two groups of 60 patients each. Internal fixation by humeral interlocking nails was performed on Group I, and internal fixation by dynamic compression plating, with or without bone grafting, was performed on Group II.

AO classification, mode of injury, level of injury, side, range of elbow joint movements, DASH score and complications in both groups were recorded. Results of the study was compiled and entered in MS excel sheet for statistical inference. Chi- square test was used for comparison of variables between two groups. P value less than 0.05 was considered significant.

RESULTS

Age group 18-28 years had 14 patients in group I and 7 in group II, 28-38 years had 18 in group I and 22 in group II, 38-48 years had 15 in group I and 20 in group II and 48-60 years had 13 in group I and 11 in group II [Table 1].

Table 1: Distribution of patients based on age group

Age group (years)	Group I (Humeral interlocking nail)	Group II (Dynamic compression plating)	Total
18-28	14	7	21
28-38	18	22	50
38-48	15	20	35
48-60	13	11	24
Total	60	60	120

Table 2: Comparison of parameters

Parameters	Variables	Group I	Group II	P value
Etiology	RTA	46	41	0.04
	Fall	10	12	
	Violence	4	7	
AO classification	A1	5	4	0.82
	A2	3	2	
	A3	22	23	
	B1	4	3	
	B2	21	18	
	B3	2	1	
	C1	1	4	
	C3	1	2	
Level of injury	Upper 1/3rd	14	19	0.74
	Middle 1/3rd	37	31	
	Lower 1/3rd	13	20	
Side	Left	32	26	0.95
	Right	28	34	
Range (in degree)	Pre- op	8- 128	4-130	0.92
	Post- op	4-134	5-130	0.11

Table 3: Comparison of DASH score

DASH score	Group I	Group II	P value
Excellent	22	32	0.05
Good	13	10	
Fair	20	16	
Poor	5	2	

Mode of injury was RTA in 46 in group I and 41 in group II, fall in 10 in group I and 12 in group II and violence in 4 in group I and 7 in group II. In 22 cases in group I and 23 in group II had A3 type of fracture and B2 was seen in 21 and 18 patients respectively. Level of injury was upper 1/3rd seen in

14 and 19, middle 1/3rd in 37 and 31 and lower 1/3rd in 13 and 20 patients in group I and II respectively. Left side was involved in 32 cases in group I and 26 in group II and right side in 28 and 34 in group I and II respectively. Range of movement pre- operatively in group I was 8-128

degrees and in group II was 4-130 degrees and post-operatively in group I was 4-134 degrees and in group II was 5-130 degrees. The difference was non-significant ($P > 0.05$) [Table 2].

In 22 cases in group I and 32 in group II DASH score was excellent, 13 cases in group I and 10 in group II had good, 20 in group I and 16 in group II had fair and 5 in group I and 2 in group II had poor DASH score. The difference was significant ($P < 0.05$) [Table 3].

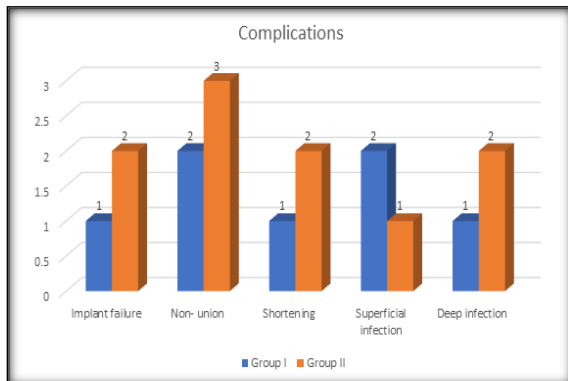


Figure 1: Comparison of complications

Complications seen were implant failure 1 in group I and 2 in group II, non-union 2 in group I and 3 in group II, shortening seen in 1 in group I and 2 in group II, superficial infection 1 in group I and 2 in group II, and deep infection 1 in group I and 2 in group II. The difference was non-significant ($P > 0.05$) [Figure 1].

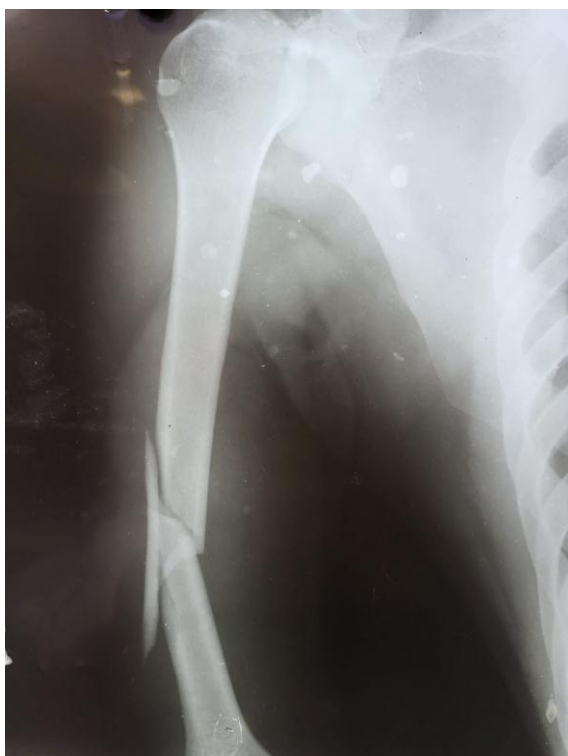

Figure 2: AO type 12B1 shaft humerus fracture

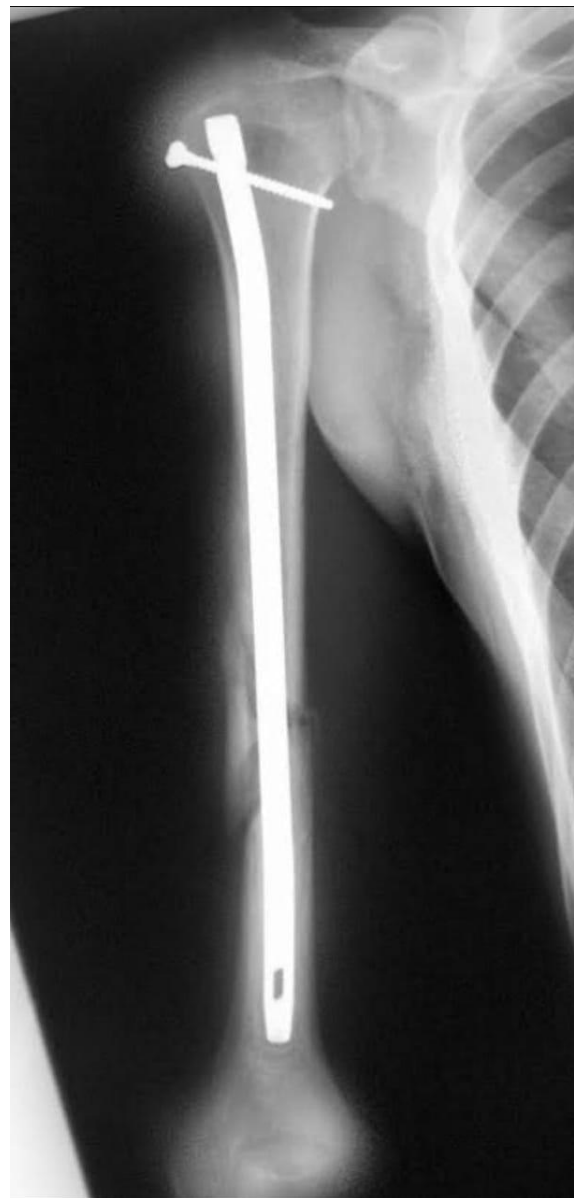

Figure 3: Managed by Humerus interlocking nail

DISCUSSION

Unacceptable fracture reduction, concomitant vascular lesions, open fractures, radial nerve palsy, polytrauma patients, floating elbow, and obese patients who are at risk of developing a varus angulation are the surgical indications.^[6] In the majority of series of humeral shaft fractures treated with closed reduction or open reduction and internal fixation, good to outstanding results have been documented. To choose the best course of action, it is important to take into account the fracture pattern, together with the patient's characteristics and any related injuries.^[7]

An easy, secure, and efficient therapy for humeral shaft non-union is anterior plating. It has a similar recovery period to previous techniques for treating humeral shaft non-union and does not necessitate substantial soft tissue dissection or radial nerve visualisation.^[8] The plate is positioned on the

anterior surface of the bone in this alternative method to osteosynthesis for humeral shaft non-union. The biological advantages of using a technique that uses a plane between nerves to lessen harm to soft tissues undoubtedly played a role in the success of the experiment.^[9] We performed present study to compare humeral interlocking nail and compression plating in fracture of shaft of humerus cases.

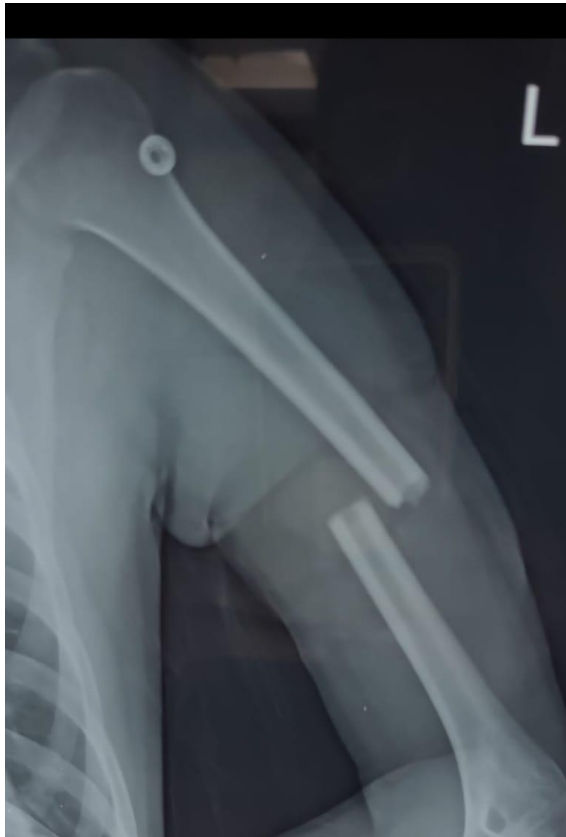

Figure 4: AO type 12A3 shaft humerus fracture

Our study showed that age group 18-28 years had 14 patients in group I and 7 in group II, 28-38 years had 18 in group I and 22 in group II, 38-48 years had 15 in group I and 20 in group II and 48-60 years had 13 in group I and 11 in group II. Mode of injury was RTA in 46 in group I and 41 in group II, fall in 10 in group I and 12 in group II and violence in 4 in group I and 7 in group II. In 22 cases in group I and 23 in group II had A3 type of fracture and B2 was seen in 21 and 18 patients respectively. In a research by Ghosh et al^[10], men outnumbered women and 40% of the cases were between the ages of 31 and 40. The most common cause (63.3%) was motor vehicle accidents. More frequently (66.6%) the right humerus was affected. The majority of patients (40%) underwent surgery 4-6 days following the incident. Out of 30 patients in the plate group, the following problems occurred: infection (6.6%), delayed union (13.3%), shoulder restriction (13.3%), and elbow restriction (6.6%). Out of 30 patients in the nail group, the following problems occurred: shoulder discomfort (46.6%), elbow pain (6.6%),

infection (6.6%), delayed union (26.6%), shoulder mobility restriction (13.3%), and splintering of the fracture end (6.6%). Maximum number of fractures were clinically united between 11 and 13 weeks (73.3% in the plating group and 60% in the nailing group). The majority of patients (73.3% plate) had radiological union between 12 and 16 weeks.

Level of injury was upper 1/3rd seen in 14 and 19, middle 1/3rd in 37 and 31 and lower 1/3rd in 13 and 20 patients in group I and II respectively. Left side was involved in 32 cases in group I and 26 in group II and right side in 28 and 34 in group I and II respectively. Range of movement pre-operatively in group I was 8-128 degrees and in group II was 4-130 degrees and post-operatively in group I was 4-134 degrees and in group II was 5-130 degrees. In their investigation, Hashib et al^[11] treated internal fixation with humeral interlocking nails in 15 patients (Group-A) and dynamic compression plating in 14 cases (Group-B), with or without bone grafting. All except one of the cases from each group resumed their old jobs. These two situations both progressed to non-union. They could go about their regular lives, but they couldn't go back to work. Thus, 92.3% of cases in both groups had good functional results, while 7.7% of cases in either group had poor results. Infections were established in 4 patients in group-B (30.8%) that were treated with dynamic compression plating. Complications were also noted in this investigation. Two of them had superficial infections that were successfully treated with antibiotics and bandages, leading to successful healing and unification. In two cases, sinuses started to discharge.

In 22 cases in group I and 32 in group II DASH score was excellent, 13 cases in group I and 10 in group II had good, 20 in group I and 16 in group II had fair and 5 in group I and 2 in group II had poor DASH score. Complications seen were implant failure 1 in group I and 2 in group II, non-union 2 in group I and 3 in group II, shortening seen in 1 in group I and 2 in group II, superficial infection 1 in group I and 2 in group II, and deep infection 1 in group I and 2 in group II. In Changulani et al^[12] study, internal fixation was performed on 23 patients using IMN and 24 using DCP. All cases involved reaming antegrade nailing. Anterolateral or posterior approaches were used for DCP. The outcome was evaluated based on the union time, union rate, functional outcome, and complication incidence. Using the American Shoulder and Elbow Surgeons' Score (ASES), functional outcome was evaluated. There was no discernible difference in the ASES scores between the two groups when the results of the independent samples t test were compared. When comparing IMN with DCP, it was discovered that the average union time was substantially shorter for IMN.

CONCLUSION

Both humeral interlocking nail and dynamic compression plating can be considered in the management of humeral shaft fractures.

REFERENCES

1. Puri SR, Biswas SK, Salgia A, Sanghi S, Aggarwal T, Kohli A. Operative management of fracture of shaft humerus by dynamic compression plate versus interlocking intramedullary nailing: A comparative prospective study of 30 cases. *Med J DY Patil Univ* 2013;6:49-54.
2. An Z, Zeng B, He X, Chen Q, Hu S. Plating osteosynthesis of mid-distal humeral shaft fractures: Minimally invasive versus conventional open reduction technique. *Int Orthop* 2010;34:131-5.
3. Putti AB, Uppin RB, Putti BB. Locked intramedullary nailing versus dynamic compression plating for humeral shaft fractures. *J Orthop Surg (Hong Kong)* 2009;17:139-41.
4. Raghavendra S, Bhalodiya HP. Internal fixation of fractures of the shaft of the humerus by dynamic compression plate or intramedullary nail: A prospective study. *Indian J Orthop* 2007;41:214-8.
5. Rommens PM, Kuechle R, Bord T, Lewens T, Engelmann R, Blum J. Humeral nailing revisited. *Top of Form Injury* 2008;39:1319-28.
6. Meekers FS, Broos PL. Operative treatment of humeral shaft fractures. The Leuven experience. *Acta Orthop Belg* 2002;68:462-70.
7. Tingstad EM, Wolinsky PR, Shyr Y, Johnson KD. Effect of immediate weight bearing on plated fractures of the humeral shaft. *J Trauma* 2000;49:278-80.
8. Bhandari M, Devereaux JP, McKee MD, Schemitsch EH. Compression plating versus intramedullary nailing of humeral shaft fractures a meta-analysis. *Acta Orthop* 2006;77:279-84.
9. Kesemenli CC, Subasi M, Arslan H, Necmioglu S, Kapukaya A. Comparison between the results of intramedullary nailing and compression plate fixation in the treatment of humerus fractures. *Acta Orthop Traumatol Turc* 2003;37:120-5.
10. Ghosh S, Halder TC, Chaudhuri A, Datta S, Dasgupta S, Mitra UK. Comparative study of operative treatment of mid shaft fracture of humerus by locking plate versus intramedullary interlocking nail. *Med J DY Patil Univ* 2013;6:390-4.
11. Hashib G. Management of humeral shaft fracture: a comparative study between interlocking nail and dynamic compression plate. *Int J Res Orthop* 2016;2:40-7.
12. Changulani M, Jain UK, Keswani T. Comparison of the use of the humerus intramedullary nail and dynamic compression plate for the management of diaphyseal fractures of the humerus. A randomised controlled study. *Int Orthop* 2007;31:391-5.